

# Case Report

---

## Remitting Form of Hemicrania Continua With Seasonal Pattern

Mario F. P. Peres, MD; Marlind Alan Stiles, DMD; Michael Oshinsky, PhD; Todd D. Rozen, MD

**Hemicrania continua is a primary headache syndrome characterized by a continuous, unilateral headache that is completely responsive to indomethacin. Hemicrania continua exists in continuous and remitting forms. Ten cases of the remitting form have been reported, none of which have had a seasonal pattern. We report a patient with remitting hemicrania continua with a clear seasonal predilection.**

**Key words:** hemicrania continua, melatonin, indomethacin, seasonal variation

**Abbreviation:** HC hemicrania continua

(*Headache* 2001;41:592-594)

---

Hemicrania continua (HC) is a primary headache syndrome characterized by a continuous, unilateral headache that is completely responsive to indomethacin.

Hemicrania continua exists in continuous and remitting forms. In 1991, Bordini et al<sup>1</sup> proposed three subtypes of HC: the remitting form and the continuous form, which is subdivided into a form which is continuous from onset and a form which evolves from the remitting form (transformed).

In the remitting form of HC, distinct headache phases last weeks to months with prolonged pain-free remissions.<sup>2</sup> The first case of HC with a remitting course was reported by Sjaastad and Tjorstad<sup>3</sup> in 1987, and was the third patient with HC reported in the literature. There was a gradual transformation from the remitting to the continuous stage, similar to the transformation of episodic into chronic migraine.<sup>4</sup>

The remitting type of HC is less common than the continuous form; the continuous: remitting ratio

is 8:1.<sup>5</sup> Ten cases of remitting HC have been reported, none of which have had a seasonal pattern. We report a patient with remitting HC with a clear seasonal predilection.

### CASE HISTORY

A 52-year-old white woman presented with a 19-year history of strictly unilateral left-sided headaches located in the ocular, frontal, and temporal regions. The pain was usually moderately severe, but the patient experienced intermittent severe exacerbations. The pain was continuous and accompanied by episodic symptoms of ipsilateral eye tearing, conjunctival injection, eyelid edema, and a feeling of "sand in the left eye." She also complained of marked photophobia, phonophobia, and nausea.

Since their onset, her headaches had presented in a seasonal pattern, starting in May and ending in July. She experienced the headaches at the same time every year, being completely headache-free from July to the next May. However, for the last 3 years, her headache periods were lasting longer and were now present until August.

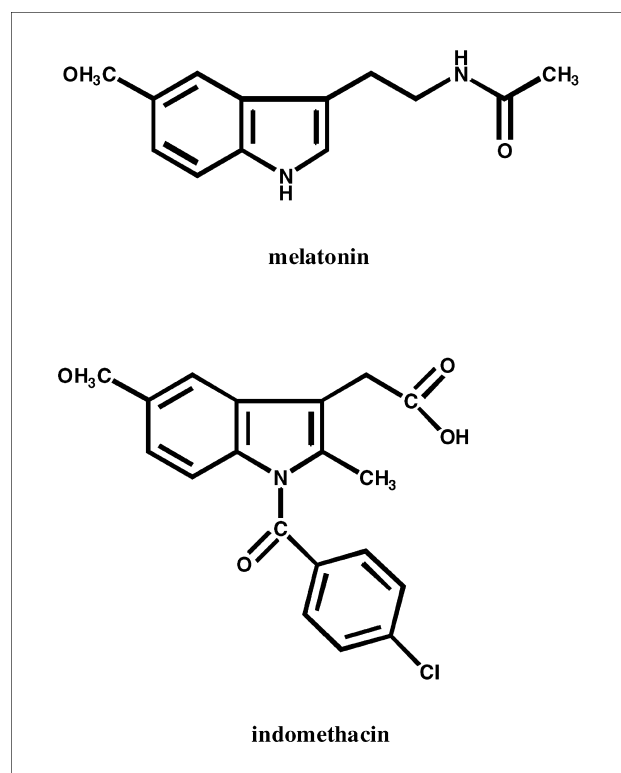
Her past medical history disclosed a mild head trauma at the age of 9 and a recent diagnosis of hepatitis C. Neurologic examination was normal except for mild neck tenderness. Occipitocervical trigger point

---

From the Jefferson Headache Center, Philadelphia, Pa.

Address all correspondence to Dr. Mario F. P. Peres, Jefferson Headache Center, 111 South 11th Street, Suite 8130, Philadelphia, PA 19107.

Accepted for publication January 7, 2001.



**Chemical structure of melatonin and indomethacin. Note the consistent methoxy indole nucleus.**

palpation did not reproduce her pain. Magnetic resonance imaging of the head was normal. The patient's pain was completely responsive to indomethacin, 75 mg per day.

## COMMENTS

Seasonal variability is reported in several neurological disorders including stroke,<sup>6</sup> multiple sclerosis,<sup>7</sup> Bell palsy,<sup>8</sup> and seasonal affective disorder.<sup>9</sup> In several headache disorders, a seasonal pattern is also present. It is a hallmark in cluster headaches<sup>10</sup> and has been described in migraine.<sup>11,12</sup>

A circannual (seasonal) variability has not previously been described in a patient with remitting HC. However, patients may not report this feature if they are not specifically questioned about it. All patients with remitting HC may have a seasonal predilection, which could represent a specific HC variant or a transition from HC to cluster headache.

The distinctive periodicity of cluster headache has strongly implicated a disturbance in the hypothalamus. The pathophysiology of HC is uncertain, but

our patient's remarkable circannual consistency supports hypothalamic involvement.

Melatonin is the most sensitive surrogate marker of circadian function in humans, and its rhythmic secretion is under the control of the hypothalamus.<sup>13</sup> Melatonin secretion is markedly influenced by seasonal changes in the light-dark cycle and plays a role in the effects of season on animal physiology and behavior.<sup>14</sup>

Decreased melatonin levels have been reported in patients with cluster headache,<sup>15,16</sup> and melatonin has been used for the prophylactic treatment of this type of headache.<sup>17</sup> Melatonin has been shown to play a role in cluster headache circannual variation.<sup>18</sup> Melatonin may have a role in the seasonal variation of remitting HC. Indomethacin and melatonin have a similar structural formula<sup>19</sup> (Figure), so indomethacin responsiveness could be related to melatonin's biological activity. Further studies regarding the role of melatonin in HC are needed. Melatonin may have a therapeutic role in HC.

## REFERENCES

1. Bordini C, Antonaci F, Stovner LJ, Schrader H, Sjaastad O. "Hemicrania continua": a clinical review. *Headache*. 1991;31:20-26.
2. Newman LC, Lipton RB, Solomon S. Hemicrania continua: ten new cases and a review of the literature. *Neurology*. 1994;44:2111-2114.
3. Sjaastad O, Tjorstad K. "Hemicrania continua": a third Norwegian case. *Cephalalgia*. 1987;7:175-177.
4. Silberstein SD, Lipton RB, Solomon S, Mathew NT. Classification of daily and near-daily headaches: proposed revisions to the IHS criteria. *Headache*. 1994;34:1-7.
5. Espada F, Escalza I, Morales-Asin F, Navas I, Iniguez C, Mauri JA. Hemicrania continua: nine new cases [abstract]. *Cephalalgia*. 1999;19:442.
6. Shinkawa A, Ueda K, Hasuo Y, Kiyohara Y, Fujishima M. Seasonal variation in stroke incidence in Hisayama, Japan. *Stroke*. 1990;21:1262-1267.
7. Goodkin DE, Hertsgaard D. Seasonal variation of multiple sclerosis exacerbations in North Dakota. *Arch Neurol*. 1989;46:1015-1018.
8. De Diego JJ, Prim MP, Madero R, Gavilan J. Seasonal patterns of idiopathic facial paralysis: a 16-year study. *Otolaryngol Head Neck Surg*. 1999;120:269-271.
9. Magnusson A. An overview of epidemiological stud-

- ies on seasonal affective disorder. *Acta Psychiatr Scand*. 2000;101:176-184.
10. Ekbom K. Patterns of cluster headache with a note on the relations to angina pectoris and peptide ulcer. *Acta Neurol Scand*. 1970;46:225-237.
  11. Fox AW, Davis RL. Migraine chronobiology. *Headache*. 1998;38:436-441.
  12. Brewerton TD, George MS. A study of the seasonal variation of migraine. *Headache*. 1990;30:511-513.
  13. Brzezinski A. Melatonin in humans. *N Engl J Med*. 1997;336:186-195.
  14. Wehr TA. Melatonin and seasonal rhythms. *J Biol Rhythms*. 1997;12:518-527.
  15. Leone M, Lucini V, D'Amico D, et al. Twenty-four-hour melatonin and cortisol plasma levels in relation to timing of cluster headache. *Cephalalgia*. 1995;15:224-229.
  16. Waldenlind E, Ekbom K, Wetterberg L, et al. Lowered circannual urinary melatonin concentrations in episodic cluster headache. *Cephalalgia*. 1994;14:199-204.
  17. Leone M, D'Amico D, Moschiano F, Fraschini F, Bussone G. Melatonin versus placebo in the prophylaxis of cluster headache: a double-blind pilot study with parallel groups. *Cephalalgia*. 1996;16:494-496.
  18. Leone M, Lucini V, D'Amico D, et al. Abnormal 24-hour urinary excretory pattern of 6-sulphatoxymelatonin in both phases of cluster headache. *Cephalalgia*. 1998;18:664-667.
  19. Kelly RW, Amato F, Seamark RF. N-acetyl-5-methoxy kynurenamine, a brain metabolite of melatonin, is a potent inhibitor of prostaglandin biosynthesis. *Biochem Biophys Res Commun*. 1984;121:372-379.